

# Hong Kong Journal of Orthopaedic Research

(An Open Access Journal for Orthopedics and Trauma Research)

## Review Article

Hong Kong J Orthop Res  
2021; 4(2): 46-51  
ISSN (e): 2663-8231  
ISSN (p): 2663-8223  
Received: 27-06-2021  
Accepted: 18-07-2021  
© 2021, All rights reserved  
www.hkorthopaedicjournal.com  
DOI: 10.37515/ortho.8231.4206

## The electrocardiogram (ECG) made easy for orthopaedic surgeons

Wafaa S Soliman<sup>1</sup>, Esraa M Ahmed<sup>2</sup>, Eslam M Ansary<sup>2</sup>, Sarah M Hussien<sup>2</sup>, Ahmed A Khalifa<sup>2,3\*</sup>

<sup>1</sup> Aljazeera Cardiac Center, Aljazeera hospital, Riyadh, Kingdom of Saudi Arabia

<sup>2</sup> Qena faculty of medicine, South Valley university, Qena, Egypt

<sup>3</sup> Orthopaedic Department, Qena faculty of medicine and University Hospital, South valley university, Qena, Egypt

### Abstract

Evaluation and interpretation of an electrocardiogram (ECG) is not formally included in the surgical residencies teaching curriculum, at least in our area. In this review, we aimed to discuss some of the basic ECG principles that could enable an orthopaedic surgeon to perform an initial assessment of an ECG trace paper and report on the ECG appearance of some common postoperative cardiovascular complications. Some reports have been published about surgeons' capability in dealing with an ECG trace paper. Since a subset of patients going under different surgical procedures being old and fragile with more susceptibility to postoperative cardiovascular complications, even in the absence of a history of cardiovascular comorbidity. Having the necessary knowledge regarding ECG assessment, a surgeon could suspect or diagnose these complications. In this review, we explained the basic concepts of cardiac electrophysiology, the typical components of an ECG trace paper, and a systematic approach to interpreting. We provided some of the commonly encountered postoperative cardiovascular complications and their appearance in the ECG trace paper. As we believe that orthopaedic surgeons should master basic ECG interpretation skills, this review will serve as an opportunity and a guide to understanding the essential components and concepts of an ECG trace paper.

**Keywords:** Orthopaedic Surgeons, ECG, electrocardiogram, Myocardial infarction, Cardiovascular complications.

### INTRODUCTION

The electrocardiogram (ECG) is a representation of the cardiac muscle electrical activity which is recorded through the placement of specialized electrodes leading to the production of waves and segments; however, this electrical activity comes before the actual cardiac muscle mechanical contraction [1-3].

Although ECG is considered one of the oldest and simplest cardiac assessment tools [1, 4], surgeons have a bad reputation regarding their incompetency in accurately detecting and diagnosing changes in an ECG [5, 6].

Incidence of postoperative cardiovascular complications after surgical procedures in general and orthopaedic in particular is not uncommon, such as angina, myocardial infarction (MI), pulmonary embolism (PE), arrhythmias like atrial fibrillation (AF), and even up to cardiac arrest (CA) [7]; this incidence is amplified if the patient had pre-existing cardiac problems [8, 9]. Missing changes or misinterpretation of ECGs could greatly influence patient management.

In a study by Raheel *et al.*, where they delivered an electronic questionnaire to doctors in different specialties (22 surgical and 16 non-surgical) containing four ECGs with a different diagnosis, they were asked to comment on the rate, rhythm, and to suggest a diagnosis. The incidence at which the surgeons answered the three comments correctly was lower than other specialties regarding the diagnosis; about 77% of the physicians got the right answer. In contrast, only 47% of the surgeons got the right answer; they recommended that formal training on ECG be included in the surgical training programs [5].

We aimed in this review to explain the basics and principles needed for an orthopaedic surgeon to initially interpret an ECG and to shed some light on the most common cardiovascular postoperative complications and their ECG presentation.

### Cardiac cycle and electrophysiology basics (Figure 1A):

Most surgeons are familiar with the letters (P, Q, R, S, and T), representing and forms the primary waves and intervals of an ECG named by Willem Einthoven [10]. To understand what these letters form in an ECG, a surgeon needs to know some basic cardiac electrophysiology principles [11, 12].

#### \*Corresponding author:

Dr. Ahmed A. Khalifa

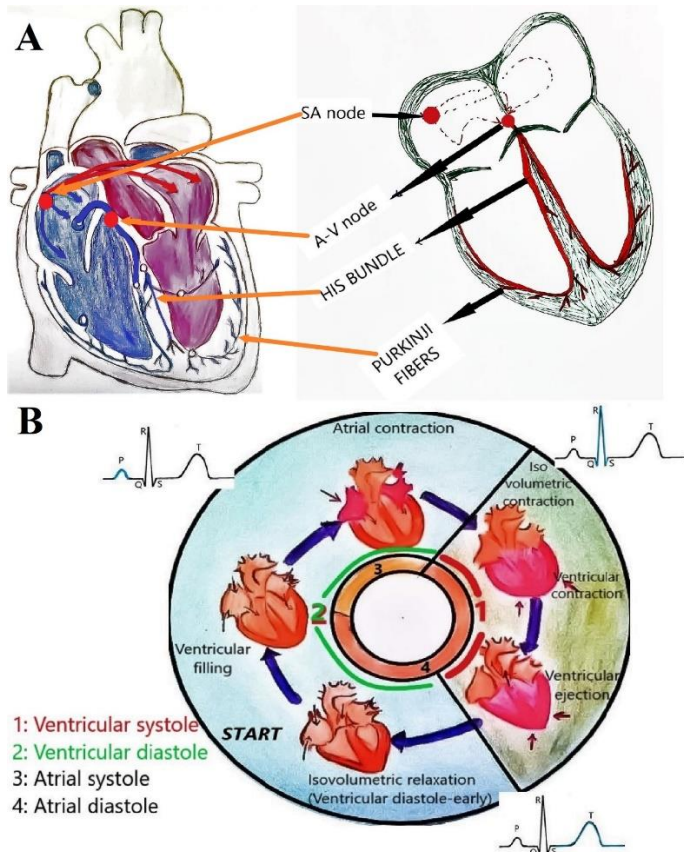
Assistant Professor and  
Consultant of orthopaedic and  
traumatology, Qena faculty of  
medicine and university  
hospital, South valley university,  
Qena, Egypt

Email:

ahmed\_adel0391@med.svu.edu

.eg

The cardiac muscle is specialized of having an automatic rhythmic contraction; in a resting cardiac muscle cell, the outside is positively charged while the inside is negatively charged; after excitation and generating an impulse, the resting state is reversed, and the outside of the cell becomes negatively charged while the inside becomes positively charged, this process is called “depolarization” when recovery of the cardiac cell starts to occur, the resting state is regained in a process called “repolarization.” These electric changes from depolarization to repolarization and vice versa are recorded as ECG waves [12, 11].



**Figure 1:** Basic electrophysiological activities of the cardiac muscles. A, the electric activity conduction system (SA: sinoatrial node, A-V: atrioventricular). B, cardiac cycle and wave produced from the electrical activity.

The cardiac electrical cycle initiating cardiac contraction begins with spontaneous depolarization in the sinoatrial node (SA) situated in the right atrium; this impulse spreads like a wave through the atrium muscles to cross the interatrial septum to reach the left atrium (this produces atrial contraction); however, it cannot spread directly to the ventricle as the atrium and ventricles are separated by an electrically inert fibrous ring and the only route for impulse transmission is through the atrioventricular (AV) node. The depolarization is then spread from the AV node carried by the bundle of His and the Purkinje fibres. The interventricular septum starts to depolarize from left to right; then, the depolarization reaches the ventricular muscle fibres starting from its endocardial surface moving outside (this produces ventricular contraction) [11].

#### Presentation of the cardiac activity as ECG waves and intervals (Figure 1B):

A single heartbeat starts with SA node depolarization; however, this activity does not produce any wave on the ECG, but as the impulse starts to spread from the SA node leading to depolarization of the atrium, the P wave is produced. As the impulse travels its way to the AV node, no wave is produced. At the AV node, the conduction is delayed as the AV node conducts impulse slowly to protect the ventricles from the spread of the rapid impulses generated in the atria, the time spent as the

depolarization wave moves from the SA node through the atria to reach the AV node then to the ventricular muscles is called the PR interval. As the depolarization impulse travels its way through the bundle of His to the interventricular septum then to the whole ventricular muscle fibres, this led to the production of the QRS complex, where the Q (first downward deflection) represents the depolarization of the interventricular septum, the R (upward deflection) and the S (second downward deflection) waves represents depolarization of the right and left ventricles, respectively. When the ventricular muscles start to repolarize to the resting electrical state, this produces a T wave [12]. After complete depolarization of the heart, the cardiac muscle must then repolarize before it can be ready to depolarize for the next cardiac cycle, worth mentioning that the atrial repolarization occurs during the PR segment and QRS complex; however, it has a very low amplitude to be detected [3, 4].

#### How is an ECG recorded?

To fully understand this issue, we should know the technique of recording using “leads” and how to read the ECG “tracing paper.”

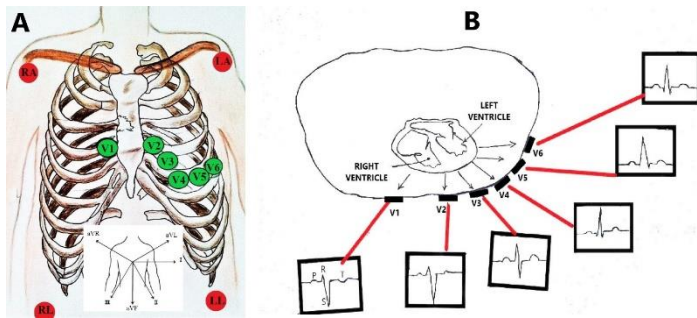
##### 1-the leads (Figure 2):

A detailed explanation and description of the electrical axis of the cardiac activities is beyond the scope of this review; however, describing the leads and their position required for recording an ECG is crucial, as if a lead is misplaced, it can result in a considerable diagnostic confusion [3, 1].

The ECG is recorded by placing a series of electrodes (wires connected to the machine) on the patient’s skin; these electrodes will provide different views or “leads” of the heart [13, 1]. The standard ECG has 12 leads (recording from 12 views or directions), where six leads are placed on the arms and/or the legs and considered as “limb leads,” they are called lead I, II, III, aVL, aVR, and aVF. The letter “a” (in aVL, aVR, and aVF) stands for “augmented,” as the readings from these leads are calculated as a combination of leads I, II, and III. Leads I, II, and III looks at the heart from the coronal plane’s sides, lead aVR looks from the patient’s right shoulder, lead aVL looks from the patient’s left shoulder, and lead aVF looks upward from the patient’s feet (Figure 2A) [12, 11].

The remaining six leads are considered “precordial leads” as they are placed on the chest (precordium); they are known as leads V1, V2, V3, V4, V5, and V6 [2]. The chest leads looks at the heart from the front and around the side, where V 1 and V 2 look at the right ventricle, V 3 and V 4 look at the interventricular septum and the anterior wall of the left ventricle and V 5 and V 6 look at the left ventricle anterior and lateral walls (Figure 2A) [12, 11].

For interpreting a 12 lead ECG, it should be taken into consideration that the direction of waves deflections (upward or downward) could be reversed according to which lead is recording the activity (depending on the direction of the electrical activity spread), so that an upward deflection will be recorded in a lead if a wave of depolarization spreads toward the positive pole of that lead, while a downward deflection will be recorded if the wave of depolarization spreads toward the negative pole of that lead (Figure 2B). Considering the P wave as an example where it represents the atrial depolarization which typically travels downward and toward the left (from 11 clock position to 5 clock position), which is the normal reflection of depolarization stimulus spreading from the SA through atrial muscle then at the AV junction. This normal electrical activity will lead to a normal sinus P wave which is upright in lead II and downward in lead aVR. In case of an abnormality, such as an ectopic pacemaker which may be present in the lower part of the atrium or the AV junction, the electrical activity will be reversed, which leads to the production of what is called retrograde P waves moving upward and to the right (reverse of the normal) This will lead to P waves that are downward in lead II and upward in lead aVR [3, 12].



**Figure 2:** Leads used for recording the cardiac muscle electrical activities. A, the position of the leads (red circles represent the limb leads, green circles represent the pericardial leads). B, A cross-section in the chest showing the position of the pericardial leads and how the shape of the wave can change from one lead to another (S wave is shown as an example).

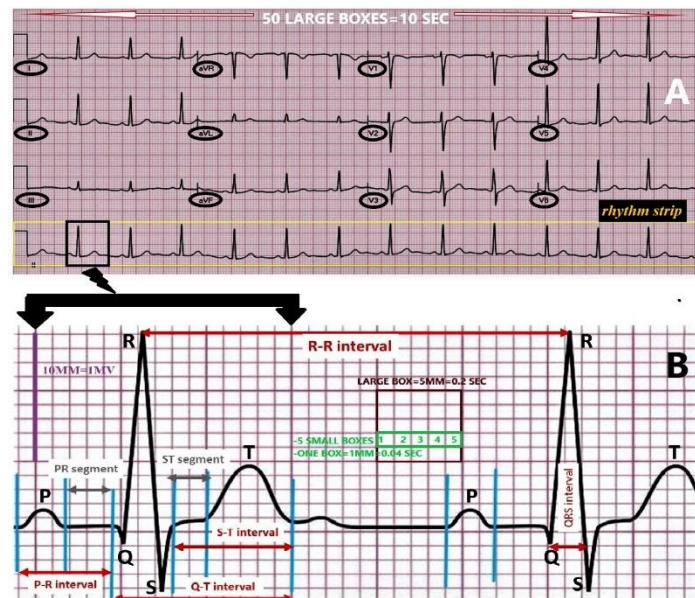
Remembering the different shapes of waves in different leads may be cumbersome for a surgeon to memorize; however, to simplify, Decker stated that analysing a 12 lead ECG will help to diagnose some pathologies like infarctions, hypertrophy, and complex arrhythmias, he

suggested that to identify the basic arrhythmias and changes analysis of lead II could be selected as it generally records the largest waves [4].

**2-understanding the ECG tracing paper (Figure 3):**

The ECG should be recorded using standard measures regarding the electrical signal amplitude and the speed at which the tracing paper moves during the recording [4]. Sticking to these roles will allow for proper assessment of different items such as heart rate and cardiac intervals and compare ECGs recorded at different times or by different machines [1, 2].

The ECG trace paper is a graph paper that moves through the ECG machine at a constant speed of 25 mm/second, a standard 12-lead ECG is a 10-second strip, where the bottom one or two lines will be a full “rhythm strip” of a specific lead (Figure 3A), spanning the whole 10 seconds of the ECG, while other leads will span only about 2.5 seconds [13]. An ECG vertical axis indicates the voltage and the deflection of the waves from the baseline, while the horizontal axis denotes time and sequence of events [12, 14].



**Figure 3:** Different components of a normal 12 lead ECG. A, a 12 leads (10-second strip) ECG trace paper showing the views from different leads and a rhythm strip is shown at the bottom. B, Different components of an ECG (waves, intervals, and segments) and the measurement units (SEC: seconds, MV: millivolts, MM: millimetre).

Generally speaking, amplitudes of the electrical activity (waves or complex) are measured on the vertical axis; the measurement unit is millivolts (mV) and could be expressed in millimetres (mm). In contrast, for measuring lengths of the intervals, it is measured on the horizontal axis, and the measurement unit is expressed in seconds or milliseconds (ms) [14].

To ease times and distances measurements, each ECG strip is divided into large boxes and small boxes; the large box is 5 mm and is equivalent to 0.20 seconds (200 ms), it is formed of five small boxes, so each small box measures 1 mm and is equivalent to 0.04 seconds (40 ms), one mV equals to 10 mm and is represented vertically by ten small boxes (Figure 3B). For an entire ECG of 10 seconds long, there must be 50 large boxes. ECG is easily interpreted by correlating the height and width of the waves or intervals with the squares [2].

**The normal ECG components (Figure 3B, Table 1):**

On an ECG tracing paper, the ECG tracing baseline is called the isoelectric

line indicating the resting membrane potential; activity is representing as deflections (downward or upward) from the isoelectric line, which are lettered in the previously mentioned alphabetical order (P-QRS-T). A normal ECG is formed of waves, intervals, segments, and one complex [2, 1, 15, 14].

**Waves:** An upward or downward deflection from the baseline indicating a specific electrical event. The waves on an ECG include the P wave, Q wave, R wave, S wave, and T wave.

**Intervals:** time measured between two specific ECG events. It includes the PR interval, QRS interval, QT interval, and RR interval.

**Complex:** This is a combination of multiple waves, the only main complex on an ECG is the QRS complex.

**Segments:** The length between two baseline points on an ECG. The segments on an ECG include the PR segment, ST-segment, and TP segment. The normal values of different components are presented in (Table 1).

Table 1: different components of the ECG trace paper (waves, intervals, and segments) showing the normal characteristics and the abnormalities occurring with various conditions.

Items	How to measure	Seen in	What does it represent	Normal Characteristics	Abnormality
<b>WAVES</b>					
<b>P wave</b>		-Best seen in lead V1 -Upward in leads I, aVF, and V3-V6.	Represents discharge of SA node and depolarization of both atria	-Upward deflection and rounded in shape. -Duration: 80 ms (one square wide and one square tall).	-if becomes wider or taller = hypertrophied atrium. -contours change between beats suggests the presence of an ectopic atrial focus -absent (with irregular rhythm) = atrial fibrillation (AF).
<b>QRS complex</b>	From the first deflection of the QRS complex to its end at the isoelectric line.	-represented by an upward deflection with a large upward R in leads I, II, V4 - V6 and a downward deflection with a large, deep S in aVR, V1, and V2  -proceeding from V1 to V6, the R waves get taller while the S waves get smaller; at V3 or V4, these waves are usually equal.	Ventricular depolarization	-Q is downward, R is upward, and S is a downward deflection. -Contour is the same between beats. -Amplitude > 0.5 mV in at least one standard lead and > 1.0 mV in at least one precordial lead. -Upper limit of normal amplitude is 2.5 - 3.0 mV -Duration: 80-100 ms (2.5 small squares).	<b>Abnormal duration:</b> -Prolonged: Bundle branch blocks, drug toxicity, electrolyte imbalance  <b>Abnormal Contour:</b> -Change of contour between beats suggests ectopic foci. -Abnormal but constant contour suggests: 1. Bundle branch blocks 2. Drug toxicity 3. Electrolyte imbalance
<b>T wave</b>		- T wave deflection should be in the same direction as the QRS complex in at least 5 of the 6 limb leads. -Upward in leads V2 - V6, downward in aVR.	Ventricular repolarization.	-Upward deflection after the QRS complex, normally rounded and asymmetrical, with a more gradual ascent than descent -amplitude of at least 0.2 mV in leads V3 and V4 and at least 0.1 mV in leads V5 and V6. -Duration: 160 ms.	-tall, peaked T waves occur with Hyperkalemia -low voltage T waves occur with Hypokalemia (Inverted T waves in precordial leads V1, V2, V3 can be seen in normal, young athletes)
<b>INTERVALS</b>					
<b>PR Interval</b>	measured from the beginning of the P wave to the beginning of the R portion of the QRS complex.		Represents impulse traveling from atria to ventricles through His bundle; the electrical impulse passes through the AV node into the ventricle during this interval.	Duration: 120–200 ms (3–5 squares). (It is inversely related to HR)	-If the PR interval is prolonged, one may deduce that AV block is present. -If shortened may indicate the presence of Wolff-Parkinson-White Syndrome (WPW) (when associated with a prolonged QRS).
<b>QT Interval</b>	measured from the first deflection of the QRS complex to the end of the T wave at an isoelectric line.		The total time taken by the ventricles to be activated (depolarization) and recover to its normal resting state (repolarization).	It varies inversely with heart rate; at 60 bpm, it is normally 420 ms or less.	A prolonged QT interval is a risk factor for ventricular tachyarrhythmia and sudden death. Prolonged QT may occur with: 1. Quinidine Toxicity 2. Hypocalcemia Shortened QT may occur with hypocalcemia.
<b>RR Interval</b>	The interval between an R wave and the next R wave		is a function of intrinsic properties of the sinus node as well as autonomic influences	0.6 to 1.2 sec at a normal resting heart rate between 60 and 100 bpm	Irregular = AF
<b>ST interval</b>	from the end of the QRS complex to the end of the T wave			Duration: 320 ms	

SEGMENTS					
<b>ST-segment</b>	from the end of the S wave to the beginning of the T wave	-never normally depressed greater than 0.5 mm in any lead.	The ST segment represents the transient period when the ventricles are depolarized, and no further electrical current passes through the muscle	Duration: 80-120 ms, isoelectric	It is important in identifying myocardial infarctions (elevations) or Ischemia (depressions). -The location of ST-segment elevation helps to identify the area of infarction: 1. V1, V2, V3, V4: Antero-Septal Infarct. 2. II, III, aVF: Inferior wall infarct. 3. V5, V6, I, aVL: Lateral Wall Infarct. 4. If elevation in all leads: suggests Pericarditis.
<b>PR segment</b>	From the end of the P wave to the start of the QRS complex		The impulse vector is from the AV node to the Bundle of His to the bundle branches and then to the Purkinje fibers. This electrical activity does not produce a contraction directly and is merely traveling down towards the ventricles, and this shows up flat on the ECG.	Duration: 50-120 ms	

ECG: electrocardiogram, SA: sinoatrial node, ms: millisecond, AF: atrial fibrillation, mV: millivolts, WPW: Wolff-Parkinson-White Syndrome,

### How to comment on an ECG:

To analyse or comment on an ECG paper, a stepwise approach should be followed; however, Becker suggested that the way to analyse an ECG strip is not uniform and sometimes it is subjective, and each clinician or surgeon may adopt a sequence of analysis [4], the evaluation of an ECG mainly include evaluating the rhythm and rate [12, 2, 16]. Here we will describe a simplified three steps to conduct a provisional ECG evaluation.

#### Step 1: Do Waves, intervals, and Complexes Progress in a Normal Sequence?

This will serve as a general view over an ECG strip; usually, each P wave should be followed by a QRS complex, followed by a T wave. This guarantees a typical sequence for each cardiac cycle [4].

#### Step 2: Is the Rhythm Regular or Irregular?

Most areas of the heart can depolarize spontaneously and rhythmically; the rhythm is determined by the part of the heart taking control which depolarizes more frequently and controls the ventricular contraction rate; usually, the SA node possesses the highest frequency, so it controls the heart rate and is called as the pacemaker of the heart. In a normal situation, the depolarization starts in the SA node, and the heart rate is then called to have a "sinus rhythm," which is characterized by a heart rate of 60-100 beats/minute, the P wave is positive in Lead II and inverted in lead aVR, and a QRS complex follows every P wave.

To start reporting on the rhythm, you may do the following:

#### A: Check the intervals:

If the intervals between QRS complexes (R-R intervals) are consistent, ventricular rhythm is regular. If intervals between P waves (P-P intervals) are consistent, the atrial rhythm is regular [4].

#### B: P waves similarity and PR intervals length:

In case that the SA node is the primary pacemaker, P waves should be similar and typical in shape, which is generating a sinus rhythm. If P waves vary in shape or even are absent, this suggests that other tissue(s) focus are functioning as pacemakers [4]. If the focus present in the atrial muscle, the produced rhythm is called an atrial escape, and the atrial

depolarization produces an abnormal P wave with normal QRS complexes [12].

The PR interval usually is 0.12–0.2 seconds (3–5 small squares). Longer intervals indicate that the impulse is being delayed from entering the ventricles, and the condition is designated AV block [4].

#### C: check the QRS complexes:

We should evaluate if they are similar and if narrowed or widened. Typically, the QRS complex duration should not exceed 0.10 seconds (about 2.5 small squares). A widened complex occurs if the ventricular muscle is hypertrophied or if the ventricular depolarization is initiated by pacemaker tissue below the AV node; it is called a ventricular rhythm. Which is characterized by the absence of P waves widened QRS complexes and abnormal T waves. [12, 4] A narrowed complex occurs if a pacemaker initiates the rhythm at the AV node or higher, called a supraventricular rhythm. If the depolarization starts in the AV node, the rhythm is called a junctional rhythm, which will be characterized by the absence of P waves with normal QRS complexes. [12] If the QRS complexes vary in appearance (dissimilarity), it indicates that more than one pacemaker is generating impulses, which is called *ectopic pacemakers*, and the rhythm is described as *ectopy* [4].

#### Step 3: Is the Rate Normal or abnormal?

Heart rate (HR) is counted as the number of ventricular contractions (presented as QRS complexes) per minute; this corresponds to the pulse rate counted clinically [12]. As the speed at which the ECG recording is adjusted at a rate of 25 mm/second. Hence, five large squares are covered per second (one large square = 0.2-second). So, in a minute (60 seconds), 300 large squares are covered (60 × 5). If the rhythm is regular, count the number of large squares between QRS complexes and divide 300 by this number. For example, if there are three large boxes between QRS complexes, the heart rate is 100 beats/min because (300 / 3=100). Similarly, if four large time boxes are counted between QRS complexes, the heart rate is 75 beats/min [12, 4].

However, if the rhythm is irregular, count the number of QRS complexes in a 6-second (30 squares) and multiply by ten; it will give the rate in 60 seconds. [12, 4] A normal sinus rhythm when the HR is between 60 and 100 beats per minute, the P waves are identifiable and having the same morphology with an RR or PP intervals being the same between beats,

rates below 60 indicate bradycardia; those above 100 indicate tachycardia [4].

#### ECG appearance of some postoperative cardiovascular complications:

As this review is mainly concerned with discussing the basics of the ECG interpretation and evaluation, we will not mention the related clinical information in detail; however, we believe that ECG is a supplement for the clinical judgment, and both should be combined to reach an accurate diagnosis of any suspected condition; findings in some of the commonly occurring postoperative cardiovascular complications are mentioned in (Table 1) [16].

#### CONCLUSION

The orthopaedic surgeon should have the necessary basic knowledge for ECG trace paper evaluation enabling early detection of cardiovascular complications which may occur in the early postoperative period. Clinical judgment should go side by side with the ECG findings.

#### Conflict of Interest

The authors declare that they have no conflict of interest.

#### Authors contribution

W.S.S and A.A.K. carried out the review idea and conception, I.A., S.M.H., E.M.A. carried out data acquisition, literature search. E.M.A. performed the hand drawings. All authors drafted the manuscript, and designed the figures and table, W.S.S. did the critical revision. All authors discussed the results and commented on the manuscript. All authors read and approved the final manuscript and are responsible for the content and similarity index of the manuscript. Authors testify that all persons designated as authors qualify for authorship and have checked the article for plagiarism.

#### No Acknowledgements

#### REFERENCES

- Price D. How to read an electrocardiogram (ECG). Part 1: Basic principles of the ECG. The normal ECG. South Sudan Medical Journal. 2010; 3(2):26-31.
- Stroobandt RX, Barold SS, Sinnaeve AF. ECG from Basics to Essentials: Step by Step. John Wiley & Sons, 2016.
- Goldberger A. Basic principles of electrocardiographic interpretation. UpToDate., 2007.
- Becker DE. Fundamentals of electrocardiography interpretation. Anesth Prog, 2006; 53 (2):53-63; quiz 64. doi:10.2344/0003-3006(2006)53[53:FOE]2.0.CO;2
- Raheel S, Safa A, Attar FG. How Good are Orthopaedic Surgeons at Interpreting ECGs? Journal of Orthopaedics, Trauma and Rehabilitation. 2010; 14(2):11-13.
- Schilling UM. Two surgeons and the ECG-a double blind study. Journal of Acute Disease. 2012; 1(1):13-17.
- Elsiw Y, Jovanovic I, Doma K, Hazratwala K, Letson H. Risk factors associated with cardiac complication after total joint arthroplasty of the hip and knee: a systematic review. J Orthop Surg Res. 2019; 14(1):15. doi:10.1186/s13018-018-1058-9
- Dzupa V, Waldauf P, Motovska Z, Widimsky P, Ondrakova M, Bartoska R, et al. Risk comparison of bleeding and ischemic perioperative complications after acute and elective orthopedic surgery in patients with cardiovascular disease. Archives of orthopaedic and trauma surgery. 2016; 136(7):907-911. doi:10.1007/s00402-016-2468-y
- Thomas S, Borges F, Bhandari M, De Beer J, Urrutia Cuchi G, Adili A, et al. Association Between Myocardial Injury and Cardiovascular Outcomes of Orthopaedic Surgery: A Vascular Events in Noncardiac Surgery Patients Cohort Evaluation (VISION) Substudy. The Journal of bone and joint surgery American. 2020; 102(10):880-888. doi:10.2106/JBJS.18.01305
- de Luna AB. Willem Einthoven and the ECG: Antoni Bayés de Luna discusses the discovery of the ECG almost 120 years ago which has remained almost unchanged to the present day. European Heart Journal. 2019; 40(41):3381-3383. doi:10.1093/eurheartj/ehz721
- Houghton A. Making sense of the ECG: a hands-on guide. CRC press, 2019.
- Hampton J, Hampton J. The ECG made easy e-book. Elsevier Health Sciences, 2019.
- Anoop UR, Ramesh, Verma K, Narayanan. The ECG made easy for the dental practitioner. Indian journal of dental research: official publication of Indian Society for Dental Research 2014; 25(3):386-389. doi:10.4103/0970-9290.138349
- Lieberman K. Interpreting 12-lead ECGs: a piece by piece analysis. The Nurse practitioner. 2008; 33(10):28-35; quiz 35-26. doi:10.1097/01.npr.0000337197.07812.92
- Meek S, Morris F. Introduction. II--basic terminology. BMJ. 2002; 324(7335):470-473. doi:10.1136/bmj.324.7335.470
- Analysis and Interpretation of the Electrocardiogram, A Self-Directed Learning Module. <https://elentra.healthsci.queensu.ca/assets/modules/ts-ecg/index.html>. Accessed 15-2-2021

Note: This is an open access article distributed under the terms of the Creative Commons Attribution-Non Commercial (CC BY-NC 4.0) License, which allows reusers to distribute, remix, adapt, and build upon the material in any medium or format for noncommercial use only, and only so long as attribution is given to the creator.